

# Photophoresis of Topical Steroids In The Treatment of Severe Forms of Lichen Ruber Planus Of Oral Mucosa

Olga V. Serikova<sup>1\*</sup>, Nikolay P. Serikov<sup>2</sup>, Elena V. Surzhenko<sup>3</sup>, Arman A. Oganessian<sup>4</sup>, Sergey N. Gontarev<sup>5</sup>

<sup>1</sup> Department of Dentistry, Belgorod State National Research University, 85, Pobedy Street, Belgorod 308005, Russia; Email: osipova@bsu.edu.ru

<sup>2</sup> Department of Dentistry, Belgorod State National Research University, 85, Pobedy Street, Belgorod 308005, Russia

<sup>3</sup> Department of Dentistry, Belgorod State National Research University, 85, Pobedy Street, Belgorod 308005, Russia

<sup>4</sup> Department of Dentistry, Belgorod State National Research University, 85, Pobedy Street, Belgorod 308005, Russia

<sup>5</sup> Department of Dentistry, Belgorod State National Research University, 85, Pobedy Street, Belgorod 308005, Russia

## Abstract

The objective of the study is to search for new methods of treatment for lichen ruber planus with high efficacy, few complications and side effects, as well as providing a long-term therapeutic effect. During 2012-2017, the authors used the method of photophoresis (red LED radiation + topical steroid) in the combination treatment of 40 patients with severe forms of lichen ruber planus. In the course of the study, patients with severe forms of lichen ruber planus were divided into 2 groups: control group (19 patients) and basic (20 people), depending on the methods of treatment. This paper is devoted to the results of treatment of severe forms of lichen ruber planus of the oral cavity: erosive-ulcerative and exudative-hyperemic, based on the use of photophoresis in combination therapy. The Russian Device Activator LED-Active 5, produced by the Voronezh company Medtorg+ LLC, was used as a source of red LED radiation. Thus, the conducted research suggests that the use of photophoresis of topical steroids in the combination treatment of severe forms of lichen ruber planus of the oral mucosa allows to shorten the terms for the elimination of the inflammatory reaction of the oral mucosa and the timing of epithelization of erosive and ulcerative elements, which increases the efficiency of treatment and the possibility of reducing the dose of corticosteroids.

## Introduction

Currently, there is an increase in the frequency of Oral lichen ruber planus is a chronic disease characterized by unspecified etiopathogenesis, persistent course, the presence of heavily flowing forms, a variety of trigger factors, frequent torpidity of the therapy, and the possibility of tumor transformation [Abramovich S.G., 2014]. In the general structure of diseases of the oral mucosa, lichen ruber planus accounts for 17 to 35%. The most common disease occurs in women aged 50 years and older. Isolated lesions of the oral mucosa in lichen ruber planus are detected in 78% of patients, more often localized in the oral cavity in the distal sections of the mucous cheeks, tongue, gums, less likely affecting the mucous palate and vermilion border [Kobzeva G.B., 2013].

The most difficult clinical problem is the development of effective methods of therapy of severe permanent-recurring forms of lichen ruber planus, refractory to corticosteroids [Molochkov V.A., 2013] or having contraindications. Severe forms of the disease are characterized by the presence of acute inflammatory phenomena and painfulness for many years, which contributes to a decrease in the quality of life of patients, eating disorders. In addition, an erosive-ulcerative form causes high risk of malignancy [Kunin V.A., 2014].

The objective of the study is to search for new methods of treatment for lichen ruber planus with high efficacy, few complications and side effects, as well as providing a long-term therapeutic effect.

Physical methods of treatment, as a rule, are able not only to exclude or substantially reduce the need for the use of various drugs of general action, but also affecting various links of the pathological process to promote regulation of impaired hemostasis, and

activation of the body's defenses [Kalinina E.S., et al, 2011]. One of these methods is photophoresis, that is, the use of light therapy in combination with medications, which has a more pronounced therapeutic effect in the treatment of various pathologies [Kunin V.A., et al, 2012].

One of the components of photophoresis is selective chromotherapy. Many experts note the high biological activity of monochromatic light, especially red, which has a powerful anti-inflammatory effect, stimulates the proliferation and epithelization of various ulcers and wounds [Khamaganova I.V., 2014].

Irradiation with red light at a wavelength of  $625 \pm 10$  nm causes electrical recharging of cell membranes.

If the light is pulsed with correctly selected parameters, these processes occur as efficiently as possible. In this case, the metabolism is repeatedly increased, due to which the healing of wounds and other injuries is accelerated, inflammations and swelling are removed, pain syndromes are reduced [Neves S.M., et al, 2014].

The sources of red LED radiation, developed in recent years, are worthy of attention, whose action is based on the application of a "soft" effect on biological tissues [Elewa, R., et al, 2011]. One of such devices is the "LED Activator "LED-active 5" (Voronezh), which in the red light mode creates a low-intensity pulsed radiation with the following parameters: wavelength -  $625 \pm 10$  nm, pulse frequency modulation - 80 Hz, radiation power density -  $140 \text{ mW/cm}^2$ . The results of clinical trials of the LED-Active 05 source (red light mode) allow recommending it for the prevention of initial caries, in the treatment of diseases of the periodontal tissues and the oral mucosa [Jajarm, H.H., et al, 2011].

As a medical component of photophoresis, topical steroids proved themselves to be good. The scientific literature presents numerous evidence of successful experience with Advantan [Jajarm H.H., et al, 2011].

## Materials and Methods

During 2012-2017, the authors used the method of photophoresis (red LED radiation + topical steroid) in the combination treatment of 39 patients with severe forms of lichen ruber planus, 16 of them had exudative-hyperemic form, 23 – erosive and ulcerative. In the course of the study, patients with severe forms of lichen ruber planus were divided into 2 groups: control group (19 patients) and basic (20 people), depending on the methods of treatment.

The control group underwent traditional therapy for lichen ruber planus with the use of systemic glucocorticosteroids. In the main groups,

photophoresis of topical steroids was included in various programs of combination treatment according to the developed protocol using a red LED radiation source - "LED activator "LED-active 05".

The protocol for conducting photophoresis using red LED radiation and a topical steroid (Advantan) developed during this study includes the following manipulations:

1) Advantan ointment (topical steroid) is applied with a spatula on erosion and oral mucosa ulcers;

2) the tip of the red light source (red LED) is placed 1-2 mm from the lesion and exposes light for two minutes per field;

3) procedures are carried out daily, the course of treatment is 10 procedures.

## Results and Discussion

The main complaints of patients with severe form of lichen ruber planus of oral mucosa and vermilion border were pain in the oral cavity of varying severity. The erosive and ulcerative form is characterized by the most severe manifestations, among which are spontaneous voluntary and induced pains (with eating, especially hard, hot, sour and sharp, brushing teeth and speech) in 100% of patients. All patients with this form complained of a constant feeling of discomfort: 95% noted a burning sensation of the oral mucosa, 46% – "tightness" of the mucous membrane, and 37% – dryness in the oral cavity.

In the exudative-hyperemic form, 95% of patients experienced spontaneous and induced pain, 89% of patients also complained of a constant feeling of discomfort, including burning of the oral mucosa, "tightness" and dryness in the oral cavity.

Analysis of the anamnesis data revealed that among the suspected causes of the onset of lichen ruber planus, 30% of patients thought that they were experiencing stress (in the family) or situations associated with increased psycho-emotional stress (in the family or at work), and 20% of patients could not indicate a provoking factor.

Analysis of the data of earlier treatment showed that it was ineffective for 50% of patients with erosive and ulcerative form – erosions were not epithelialized, and low-effective for 48% of patients with erosive ulcerous form and 67% with exudative-hyperemic (remission less than 3 weeks). A small effect of the treatment conducted contributed to the formation of a negative psychological mood in 28% of patients and the opinion that "a positive therapeutic effect is impossible".

Erosive and ulcerative form in the severe course of the disease was more common, in 60% of cases, characterized by a pronounced inflammatory reaction with edema and hyperemia of the mucosa and

vermilion border. Against the backdrop of inflammation, there were erosions and ulcers of round or polygonal shape, covered with fibrinous plaque, after removal of which bleeding was noted. Around the erosive and ulcerative elements and in other anatomical zones of the oral mucosa there were typical for lichen ruber planus papules, merging into various patterns. According to the examination, photorecording and topography of the elements of the lesion, this form was more often found on the mucous membrane of the cheeks in the retro-molar area, along the line of teeth closing and on the lateral surfaces of the tongue.

Exudative-hyperemic form was less common in severe cases and in 40% of cases when the hyperemic, edematous mucous membrane of the mouth had typical papules that merged into plaques or a characteristic pattern.

All 100% of patients suffering from severe forms of oral lichen ruber planus and vermilion border had concomitant diseases of internal organs and systems.

Reduction of pain sensations in erosive-ulcerative form in 7 patients of the main group was noted on the 7th day, and the final relief of pain was noted on day

15 of treatment in 10 patients. One patient maintained pain and burning sensation (1-3 points on the visual analogue scale). In exudative hyperemic form, pain reduction in 8 patients in the main group was on day 7, the final pain relief was noted in 9 patients on day 10 (table 1).

In the main groups, the decrease in the inflammatory response from the mucous membrane with erosive ulcerous form was noted on day 7 of treatment in 5 patients, on day 10 – in 8, and on day 15 – in 9 patients. Complete relief of the inflammatory reaction of oral mucosa was noted on day 30 in 10 patients. A moderate inflammatory reaction persisted in one patient, a transition from the ulcerative form to the hyperemic was observed. With exudative hyperemic form, the decrease in the inflammatory reaction from the mucous membrane of the mouth was noted on day 7 of treatment in 6 patients, and on day 10 – in 8 patients. Complete relief of the inflammatory reaction of oral mucosa was noted on day 15 in 9 patients, there was a transition from the hyperemic form to the typical, characterized only by the presence of a papular pattern on an intact mucosa (table 1).

**Table 1.** Dynamics of clinical picture indices in patients of the main group (39 patients – 100%)

Days	Reduction or disappearance of patient complaints		Reducing signs of inflammation	
	erosive ulcerous form (11 patients)	exudative hyperemic form (9 patients)	erosive ulcerous form (11 patients)	exudative hyperemic form (9 patients)
7	7 (17.9%)	8 (20.5%)	5 (12.8%)	6 (15.4%)
10	8 (20.5%)	9 (23.1%)	8 (20.5%)	8 (20.5%)
15	10 (25.6%)	9 (23.1%)	9 (23.1%)	9 (23.1%)
30	10 (25.6%)	9 (23.1%)	10 (25.6%)	9 (23.1%)

In the control group with an erosive ulcerative form, reduction in pain was observed by day 7 in 5 patients, the final relief of pain was noted by 15 days in 8 patients. One patient maintained pain and burning sensation. With exudative-hyperemic form in this group, 5 patients had pain relief in 7 days, the final relief of pain was noted in 7 patients on day 15 (table 2).

Reduction of the inflammatory reaction from the mucous membrane of the mouth in the control group in patients with erosive ulcerous form was noted on day 7 of treatment in 4 patients, on day 10 – in 6, on day 15 – in 8 persons. Complete relief of the inflammatory reaction was noted on day 30 in 10

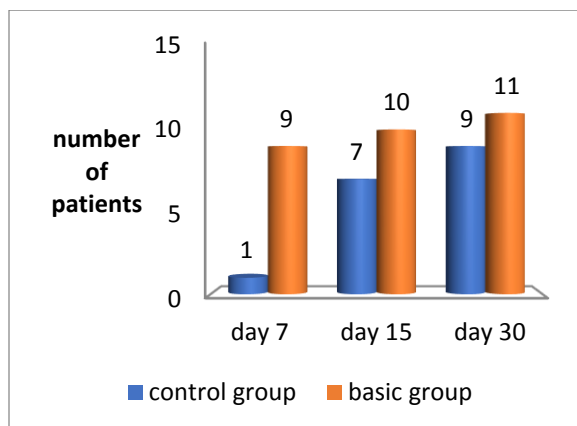
patients. Moderate inflammatory response was retained in 2 patients studied, the transition from the ulcerative form to the hyperemic was detected. With exudative hyperemic form, the decrease in the inflammatory reaction from the mucous membrane of the mouth was noted by the 7th day of treatment in 4 patients, by 10th day – by 4, by 15th day – in 5 persons. Complete relief of the inflammatory reaction of the oral mucosa was noted by the 30th day in 6 patients, a transition from the exudative-hyperemic form to a typical form was observed, characterized only by the presence of a papular pattern on the unmodified mucosa (table 2).

**Table 2.** Dynamics of clinical picture indices in patients of the control group (39 patients – 100%)

Days	Reduction or disappearance of patient complaints		Reducing signs of inflammation	
	erosive ulcerous form (11 patients)	exudative hyperemic form (9 patients)	erosive ulcerous form (11 patients)	exudative hyperemic form (9 patients)

	erosive ulcerous form (12 patients)	exudative hyperemic form (7 patients)	erosive ulcerous form (12 patients)	exudative hyperemic form (7 patients)
7	5 (12.8%)	5 (12.8%)	4 (10.3%)	4 (10.3%)
10	6 (15.4%)	6 (15.4%)	6 (15.4%)	4 (10.3%)
15	8 (20.5%)	7 (17.9%)	8 (20.5%)	5 (12.8%)
30	10 (25.6%)	7 (17.9%)	10 (25.6%)	6 (15.4%)

The course of the healing process of erosive-ulcerative elements of oral mucosa in groups was estimated by the number of patients with signs of epithelization during control examinations. Seven days after the start of treatment, in the control group with the erosive-ulcerative form, the epithelialization of lesions was observed in one patient, in the main group with erosive-ulcerative form – in 9 patients. The control observation of patients within 15 days after the start of treatment revealed epithelization of erosive and ulcerative elements in 7 control patients, and in 10 patients in the main group. Upon examination at the end of the course of combination therapy, after 30 (21) days, complete epithelialization of the pathological elements of oral mucosa was established in 9 patients in the control group, and in 11 of patients in the main group (fig. 1).



**Fig. 1.** Dynamics of the healing process of erosive and ulcerative elements in groups

Thus, the process of epithelization of erosive and ulcerative elements in erosive and ulcerative form in patients was most active when used in the combination treatment of photophoresis of topical steroids. Healing effect was especially pronounced with single erosions and ulcers on the oral mucosa and vermilion border.

The terms of the final epithelization of erosive and ulcerative elements in the erosive-ulcerative form in the observation groups were  $14 \pm 3$  days, in the control group –  $17 \pm 4$  days. All patients well tolerated photophoresis. No side effects were observed during and after the procedures.

## Conclusion

Cytological examination of smears confirmed the positive dynamics of photophoresis. The smears taken before treatment from the surface of erosions and ulcers of patients having undergone photophoresis procedures included large epithelial layers with a fine-grained oxyphilic cytoplasm and a multitude of non-nuclear epithelial cells. Stroma within the reservoir was intensely infiltrated by small-nucleated cells with a significant admixture of leukocytes. On day three after the action of red LED light and the topical steroid Advantan, there were signs of positive dynamics, as evidenced by a decrease in the number of leukocytes. Among the epithelial cells, almost all cells had well expressed nuclei, infiltration of the stroma was poorly expressed. On day seven, the smears of patients showed accelerated dynamics, which was confirmed by the absence of epithelial layers, the further increase in epithelial cells with a well-preserved structure. After the 10th treatment session, cytologic examination was used to determine mainly separately lying epithelial cells with a well-preserved structure and a small number of clumps of loosely arranged similar cells.

Thus, the conducted research suggests that the use of photophoresis of topical steroids in the combination treatment of severe forms of lichen ruber planus of the oral mucosa allows to shorten the terms for the elimination of the inflammatory reaction of the oral mucosa and the timing of epithelization of erosive and ulcerative elements, which increases the efficiency of treatment and the possibility of reducing the dose of corticosteroids.

## References

- [1] Abramovich, S.G., 2014. Phototherapy. Irkutsk: RIOFGBU "NCRVKh" SORAMN,: 200 (In Russian).
- [2] Kalinina, E.S., Arutiunian, K.E., Kumirova, O.A., Kunin, A.A., Pankova, S.N., Popova, T.A., Selin, R.V., 2011. Influence of red diode light on factors of local protection of the oral mucosa in combination therapy of oral lichen ruber planus.

- Bulletin of New Medical Technologies, 18(2): 192-194(In Russian).
- [3] Kobzeva, G.B., 2013. Dynamics of clinical parameters of the state of the parodont when using modulated red diode light with the help of the device "LED Activator "LED-active 03". Modern medicine: topical issues, 21:46-53 (In Russian).
- [4] Molochkov, V.A., Sukhova, T.E., Molochkova, Iu.V., 2013. Clinical features of lichen ruber planus. Clinical dermatology and venereology, 4:34-42 (In Russian).
- [5] Kunin, V.A., 2014. The use of monochromatic red light to correct the inflammatory conditions of periodontal tissues during the implementation of orthodontic treatment. Stomatology of the Slavic states: proceedings of the VII International Scientific-Practical Conference: 190-192.(In Russian)
- [6] Kunin, V.A., Provotorov, V.M., Pankova, S.N., 2012. Physiotherapy of dental diseases. Voronezh: 261 (In Russian).
- [7] Khamaganova, I.V., 2014. Advantan (methylprednisolona aceponate) in combination treatment of lichen ruber planus. Clinical dermatology and venereology, 3:53-54 (In Russian).
- [8] Neves, S.M., Nicolau ,R.A., Martins Maia Filho, A.L., Mendes, L., Veloso, A.M., 2014. Digital photogrammetry and histomorphometric assessment of the effect of non-coherent light (light-emitting diode) therapy ( $\lambda 640 \pm 20$  nm) on the repair of third-degree burns in rats. Lasers Med. Sci, 29 (1) :203-212.
- [9] Elewa, R., Altenburg, A., Zouboulis, C.C., 2011. Recalcitrant severe erosive cutaneous lichen planus treated with extracorporeal photopheresis monotherapy. Dermatol, 165 (2): 441-443.
- [10] Jajarm, H.H., Falaki, F., Mahdavi, O., 2011. A comparative pilot study of low intensity laser versus topical corticosteroids in the treatment of erosive-atrophic oral lichen planus. Photomed. Laser Surg, 6 (29): 421-425.
- [11] Mamalis, A., Jagdeo, J., 2015. Light-emitting diode-generated red light inhibits keloid fibroblast proliferation. Dermatol. Surg, 4 (11): 35-39.