

**Original Article**

# **Evaluation of Rat Brain Morphology Following the Induction of Acute Meningitis Treated with Ceftriaxone**

**Agarkova, A. A<sup>1</sup>, Tverskoi, A. V<sup>1\*</sup>, Morozov, V. N<sup>1</sup>, Tverskaya, A. V<sup>1</sup>, Morozova, E. N<sup>1</sup>,  
Mukhina, T. S<sup>1</sup>**

*1. Belgorod State University, 308015, Russia, Belgorod, Pobeda St. 85*

Received 9 August 2021; Accepted 14 September 2021  
Corresponding Author: tverskoy@bsu.edu.ru

---

## **Abstract**

The soft and delicate tissue of the brain, which is the center of our coordination, is protected by its surrounding layers. The disruption of these layers results in complicated situations and serious health problems. The brain has three protective layers of bone or skull tissue, the blood tissue layer, and finally the meningeal layer. The layer of blood tissue contains the blood vessels that are located between the skull and the meningeal membranes. If germs or foreign matter enter the fluid through the blood vessels under any circumstances and cause infection, the bones that protect the meninges will break and cause tissue damage. The present study aimed to assess the histological and immunohistochemical characteristics of the brain of rats that underwent induced acute purulent pneumococcal meningitis after antibiotic therapy with Ceftriaxone. A number of 20 white adult male Wistar rats were assigned to three groups. The first group (n=5) regarded as the control were injected with a saline solution into the subarachnoid space in an equivalent amount. The second and third groups of rats (n=5 and 10, respectively) were infected with acute purulent meningitis by the injection of 10 µl of *Streptococcus pneumoniae* (*S. pneumoniae*) suspension into the subarachnoid space of the brain using a 23-G needle. The various areas of the brains of rats after meningitis induced by *S. pneumoniae* were examined after the treatment with Ceftriaxone. The *S. pneumoniae* culture was injected into the subarachnoid space in the area of the rhomboid fossa. Treatment started 18 h after the injection. On day 10, a repeated puncture was performed with the analysis of cerebrospinal fluid in order to confirm the absence of meningitis; thereafter, the animals were taken out of the experiment. No signs of meningitis were found on histological examination. Mild perivascular and pericellular focal edema were revealed with signs of overload of the lymphatic system in the brain and focal ischemic changes in neurons. The investigation of expression with caspase-3 revealed a positive reaction of individual neurons. A positive reaction with antibodies to NeuN and Doublecortin was detected in most neurons; moreover, Glial fibrillary acidic protein (GFAP)-positive astrocytes and their processes were visualized in all layers of the brain substance. The reaction with neuron-specific enolase (NSE), microtubule-associated protein 2 (MAP-2), CD 31, and CD 34 was negative. Typical structure and pictures pointed to an intact brain and purulent meningitis in the first and second groups. The microscopic image and the changes revealed during immunohistochemistry by dual corticosteroid antibodies and neuronal nuclear protein were characterized by predominantly cytoplasmic and perinuclear reactions, respectively. Some neurons are positive for caspase-3 and are related to changes in the characteristic of premature aging.

**Keywords:** Acute meningitis, Ceftriaxone, Immunohistochemical markers, Brain of rats

---

## **1. Introduction**

Acute meningitis is the inflammation of the leptomeninges of an infectious origin, accompanied by

fever, intoxication, increased intracranial pressure, and inflammatory changes in the cerebrospinal fluid. In terms of prevalence, it ranks second after

meningococcal meningitis and often occurs with the involvement of the white and gray matter of the brain in the form of meningoencephalitis (1), leading to the activation of caspases, mitochondrial damage, disruption of cellular homeostasis, and initiation of apoptosis (2). Although meningitis is most often caused by a viral infection, it can also be triggered by bacterial or fungal infections (3, 4). Sometimes meningitis improves within a few weeks without treatment; nonetheless, some meningitis cases are life-threatening and require emergency treatment with antibiotics (5-7). Bacterial meningitis is a serious problem which can result in death within a few days if not treated promptly with antibiotics. Delayed treatment increases the risk of permanent brain injury or death (8, 9).

Different types of bacteria can cause acute bacterial meningitis, the most common of which is *Streptococcus pneumoniae* (Pneumococcus) (10, 11). This bacterium is the most common cause of bacterial meningitis in infants, young children, and adults (12, 13). This bacterium is more likely to cause pneumonia, as well as ear and sinus infections (14). Vaccination can help prevent infection caused by this bacterium (15, 16). Another type is *Neisseria meningitidis* (meningococcus) which is usually responsible for upper respiratory tract infection; however, it can also cause meningococcal meningitis in cases where it enters the bloodstream. It is a highly contagious infection that affects most adolescents and young adults. The infection can result in local epidemics in university dormitories, boarding schools, and military bases. Vaccination can help prevent infection caused by this bacterium (17-19).

Viral meningitis is usually mild and resolves on its own. The majority of cases are caused by enteroviruses and mostly occur in late summer and early fall. Moreover, such viruses as herpes simplex virus (Apes), AIDS, mumps, and some other viruses can also result in viral meningitis (20, 21). Underdeveloped organisms that attack the membranes and fluid around the brain also cause chronic meningitis which occurs over two weeks or more, and its symptoms are similar to those of

acute meningitis (22-24). Another type of meningitis is fungal meningitis which is relatively uncommon and causes chronic meningitis. Fungal meningitis is not contagious (25, 26), and it is sometimes similar to bacterial meningitis. Cryptococcal meningitis is the most common form of this type of meningitis which affects people with immune system defects, such as AIDS. This type of meningitis can be life-threatening if left untreated with an antifungal drug (23, 27-29).

The NeuN (neuronal nuclei) is localized in the nuclei and perinuclear cytoplasm of most mammals, as well as in dendrites, but with a lower intensity of expression in immunohistochemical studies (30). The NeuN protein is often used as a marker of postmitotic neurons (31). Proteins associated with microtubules are located in the perikaryon, dendrites, and the initial section of the axon. They are neuronal markers studied during stem cell differentiation and transplantation; nevertheless, changes in these markers, as well as many others, have been insufficiently studied in combination with meningitis (32).

It is known that acute meningitis can be complicated by encephalitis, followed by long-term rehabilitation and recovery, as well as morphological changes in the white and gray matter of the brain. In this regard, the present study aimed to assess the histological and immunohistochemical characteristics of the brain of rats that underwent experimental acute purulent pneumococcal meningitis after isolated antibiotic therapy.

## 2. Material and Methods

The current study was conducted on 20 adult male Wistar rats which were assigned to three groups. The first group (n=5) regarded as the control were injected with a saline solution into the subarachnoid space in an equivalent amount. The second and third groups of rats (n=5 and 10, respectively) were infected with acute purulent meningitis by the injection of 10 µl of *S. pneumoniae* suspension into the subarachnoid space of the brain using a 23-G needle. Antibacterial treatment started 18 h after the commencement of the experiment

with Ceftriaxone at a dose of 100 mg/kg of body weight for 7 days. The absence of meningitis was confirmed by a bacteriological examination of the cerebrospinal fluid. The animals were taken out of the experiment after 24 h and on the 11<sup>th</sup> day. Microscopic examination and photoprotection were performed on preparations stained with hematoxylin and eosin after standard histological tracing using a Nikon Eclipse Ni microscope and Nis-Elements BR 4.60.00 software. For morphological examination, the brain was taken out and fixed in 10% neutral buffered formalin for 24-48 h. Following that, the preparation was subjected to standard wiring on a Leica TP 1020 apparatus, embedded in paraffin. Sections at a thickness of about 4-5  $\mu\text{m}$  were prepared and stained with hematoxylin and eosin, as well as toluidine blue in the Nissl modification, using standard protocols and techniques on Leica EG 1150 H apparatus, Leica RM 2245, Leica autostainer XL.

Immunohistochemical reactions were performed with antibodies GFAP (clone EP672Y, CellMarque), NSE (clone MRQ55, CellMarque), p53 (clone DO7, CellMarque), Ki 67 (clone NE14, Biogenex), NeuN (polyclonal antibodies, CellMarque), MAP-2 (clone M13, CellMarque), Doublecortine (clone 2g5, CellMarque), Caspase-3 (clone EP410, CellMarque), CD 31 (clone JC70, CellMarque), CD 34 (clone QBEnd / 10, CellMarque). The labeled streptavidin-biotin (LSAB) method, diaminobenzidine was employed as a chromogen for immunohistochemical staining. Unmasking of antigens was performed by heating in citrate buffer (pH = 6.0) for 40 min at a temperature of 93°C-95°C. An immunohistochemical study was performed in the Department of Immunohistochemistry of the Belgorod Regional Anatomical Bureau (TS Mukhina). Photorecording was performed on a Mirax Desk scanner (Carl Zeiss Microimaging GmbH, Germany), a Nikon Eclipse Ni microscope, and Nis-Elements BR 4.60.00 software. Statistical calculations were performed in Statistica 10.0.

### 3. Results and Discussion

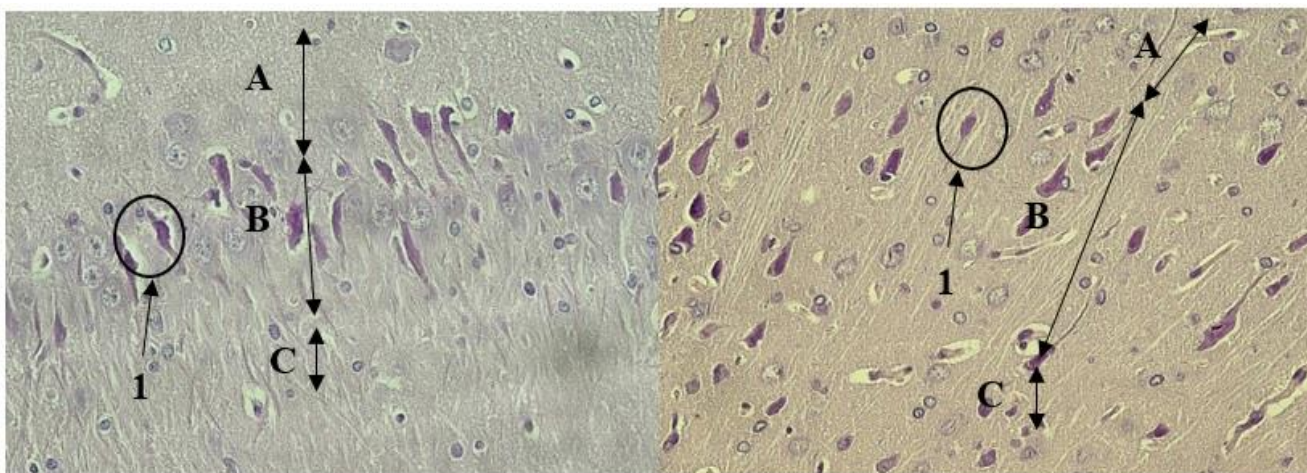
The morphological examination of the brain in the first group was similar to that in healthy animals in terms of both gray and white matter, as well as the hippocampus. A three-layer structure was preserved in the proximal large-cell (corresponds to fields CA2, CA3) and distal small-cell regions (equivalent to field CA1). The molecular, pyramidal, and marginal layers were well differentiated. It is worth noting that non-pyramidal neurons are detected in the molecular layer at a great distance from each other and they are separated by nerve fibers. In the pyramidal layer, neurons of the same name prevailed, while nerve fibers and single non-pyramidal neurons mainly dominated in the marginal zone. These structural features were similar to the brain morphology of healthy adult rats (33).

As evidenced by the result of the present study, it was indicated that the recovery of animals in all groups occurred on the 10th day of antibiotic therapy. Histological examination was performed 24 h after the commencement of the experiment and on day 11. No significant macro- and microscopic changes were observed in the first group of animals. In the second group, macro- and microscopic changes in the brain were consistent with the classical description of this process performed by M.A. Skvortsov (34). They manifested themselves in the following changes: macroscopically, the meninges were dull and full-blooded, while in terms of microscopy, they revealed a sharp expansion and venous plethora of meninges, lined with endothelium with flat nuclei.

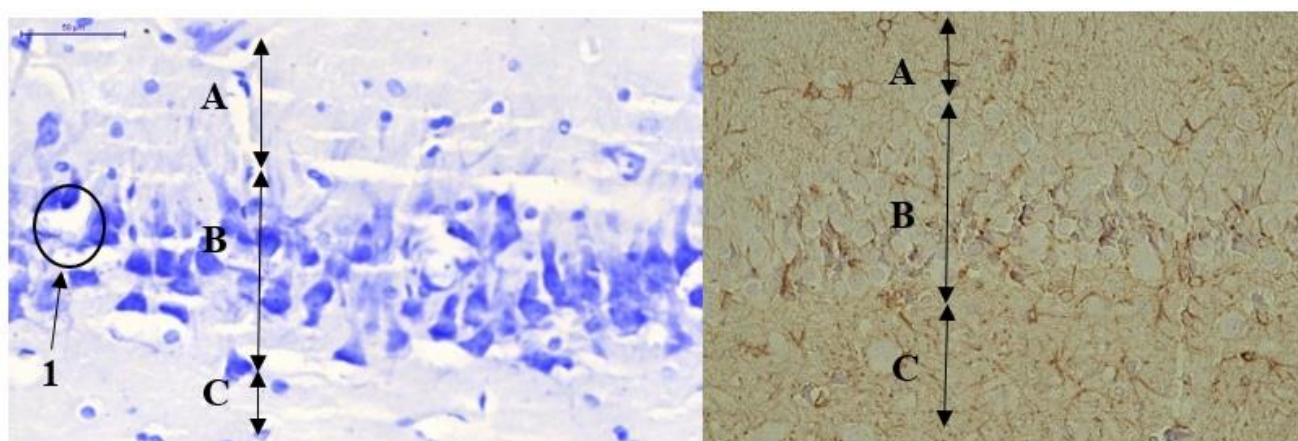
Erythrocyte stasis was observed in hemocapillaries and venules. In arterial Intima, endotheliocytes are hypertrophied, and their large nuclei bulge into the lumen of the vessel. Focal diapedesic hemorrhages, numerous blood vessels of the microvasculature, and pronounced perivascular edema are determined in the brain. The marginal glial membrane, in the structure of which the elongated nuclei of astrocytes are visible, separates the brain tissue. Glial cells and a small

number of full-blooded capillaries are scattered in the gray matter of the cortex. Rounded neurons of various shapes with rounded nuclei and nucleoli are not always visible in the outer granular layer of the cortex. The shape and size of the nuclei significantly predominate over the perikarya. Some of the pyramidal neurons can be traced from the apex of the deformed pyramids with the phenomena of pycnotic deformation of the nuclei, and laterally, short dendrites. Another part of neurons is sharply hyperchromatic, and the nuclei are not traced in them (Figure 1).

Damaged neurons with karyopyknosis predominate in the CA1 and CA3 regions of the hippocampus. Furthermore, rare neurons are observed in the form of shadow cells, but with distinct large nucleoli. Typical pyramidal neurons with large nuclei and one or two nucleoli, well-defined dendrites extending from the apex of the pyramids, and an axon from the base are found in smaller numbers, indicating a high functional load (35-37). The number of glial cells is small here. The vessels of the microvasculature are full-blooded, with perivascular edema (Figure 2).



**Figure 1.** Neuronal degeneration of CA1 area of the hippocampus and cerebral cortex on the 11<sup>th</sup> day: **A** – molecular layer, **B** – pyramidal layer, **C** – marginal layer, 1 – hyperchromatic shrunken neuron; Hematoxylin & eosin. A, B×400.



**Figure 2.** 11<sup>th</sup> day. Neuronal degeneration of CA1 area of the hippocampus (**A** – Nissl reaction) and IHC GFAP-positive reaction: **A** – molecular layer, **B** – pyramidal layer, **C** – marginal layer, 1 – hyperchromatic neuron; A, B×400.

Therefore, on the model of experimental meningitis, it was observed that secondary ischemic and toxic lesions of neurons in the cortex and hippocampus accompany typical histological changes in the membranes. Moreover, in all sections, there is pronounced perivascular and pericellular edema, clearly visible when stained with hematoxylin and eosin. Microscopic examination of the brain of the rats in the third group revealed that pyramidal neurons are located in all layers, except for the molecular one. They have a typical structure and different sizes from small (multiform layer, outer granular and pyramidal layers) and medium (outer and inner granular layers, outer pyramidal layer) to large (inner pyramidal layer) neurons.

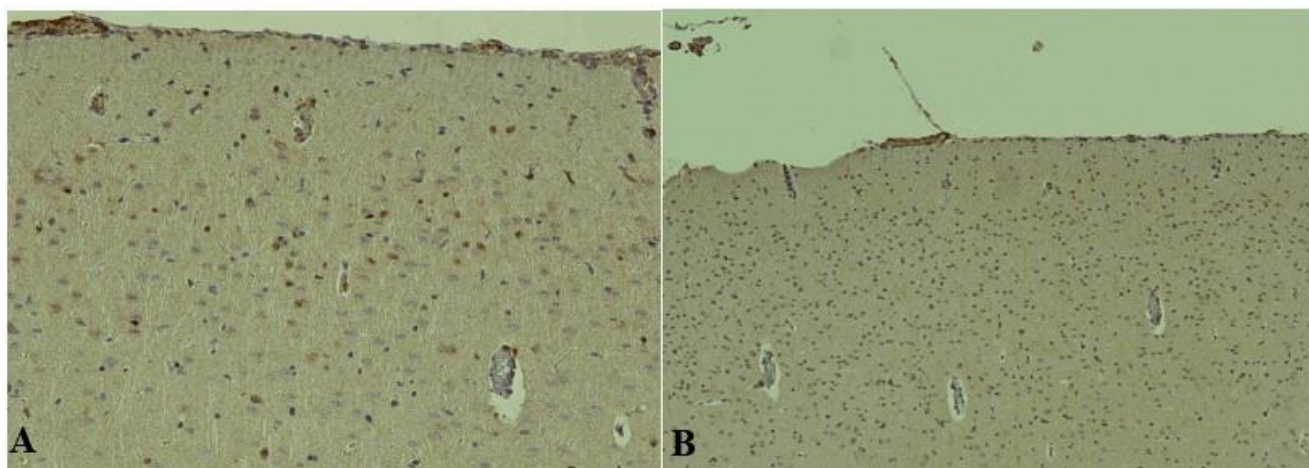
Moreover, non-pyramidal neurons are found in all layers of the cortex. Therefore, in the upper layers, mainly small horizontal cells are located at a considerable distance from each other. The dense clusters of nerve fibers divide the space between the bodies of these neurons. In the outer granular layer, granular neurons predominate, while a small number of them are revealed in the inner pyramidal layer. Stellate neurons predominate in the outer pyramidal and inner granular layers. A large number of fusiform neurons are found in the multiform layer. The cytoplasm is rich in chromatophilic substances, which manifest themselves in varying degrees. In small, medium, and large cells, these accumulations are distributed in the form of grains throughout the cytoplasm. According to the literature, the amount of basophilic substance in neurons is mainly determined by the intensity of the functional activity of one or another type of nerve cells (33).

According to the degree of cytoplasmic chromophilia, the ratio of normochromic (moderate staining of the cytoplasm) and hyperchromic (intense staining of the cytoplasm) neurons on the site of the preparation is visually the same. Hyperchromic

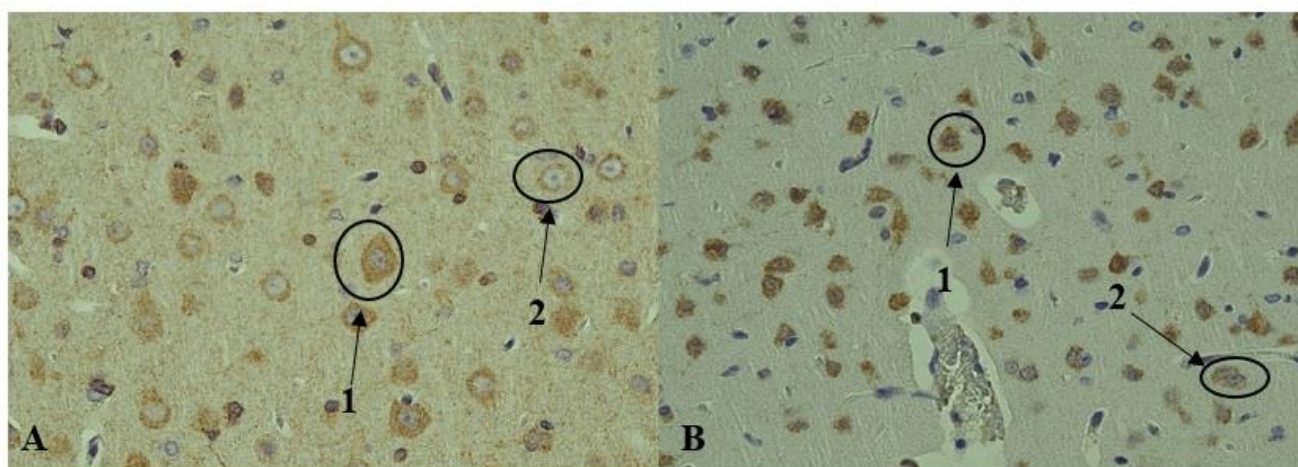
shrunken, hypochromic (weak staining), and shadow cells (very weak staining of the cytoplasm) are very rare. The number of hyperchromic neurons can increase under experimental exposure. This can be considered a hyperfunction of neurons and their reversible state (33, 38). Pronounced perivascular and pericellular edema was revealed in the second and third groups.

An immunohistochemical study with antibodies to glial fibrillar acidic protein (GFAP) revealed positive staining of glial elements and their processes, without visible differences from those in the second group. The reaction with neuron-specific enolase (NSE) antibody and Microtubule-associated protein 2 (MAP2) was negative. The reaction with antibodies to caspase-3 was positive in some neurons (Figure 3). A positive cytoplasmic reaction with antibodies to doublecortin was detected in most neurons of all layers of the brain substance in the form of fine-granular staining. In some neurons, the staining had a clearly pronounced perinuclear character. The staining was diffuse in single neurons where the structure of the nucleus was not determined. The reaction with antibodies to the nuclear neuronal protein NeuN revealed an intense cytoplasmic reaction, more pronounced perinuclear (Figure 4). An identical negative reaction with antibodies to CD 31 and CD 34 took place on the 11th day of the experiment in the capillaries of the brain substance.

In conclusion, a typical structure of an unchanged brain and a typical picture of purulent meningitis were revealed in the first and second groups. Moreover, the microscopic image, as well as the changes revealed during the immunohistochemical study with antibodies to doublecortin and neuronal nuclear protein, characterized by pronounced, mainly cytoplasmic and perinuclear reactions, respectively. Some neurons are positive for caspase-3 consistent with the changes characteristic of premature aging.



**Figure 3.** 11<sup>th</sup> day. IHC reaction with Caspase-3 (A) and MAP-2 (B) antibodies. A×200, B×100



**Figure 4.** 11<sup>th</sup> day. IHC reaction with Doublecortin (A) and NeuN (B) antibodies: 1 – intensive positive reaction in hyperchromic neurons, 2 – positive reaction in normochromic neurons. A, B×400.

#### Authors' Contribution

Study concept and design: A. A. A.

Acquisition of data: A. V. T.

Analysis and interpretation of data: V. N. M.

Drafting of the manuscript: A. V. T.

Critical revision of the manuscript for important intellectual content: E. N. M.

Statistical analysis: T. S. M.

Administrative, technical, and material support: A. A. A.

#### Ethics

All the procedures were approved by the Ethics Committee at the Belgorod State University, Belgorod,

Russia.

#### Conflict of Interest

The authors declare that they have no conflict of interest.

#### References

1. Krukovskiĭ B, Salamov G. Morphology of pneumococcal meningitis in adults. *Arkh Patol.* 1989;51(1):55-7.
2. Rusai K, Prókai Á, Szebeni B, Fekete A, Treszl A, Vannay Á, et al. Role of serum and glucocorticoid-regulated kinase-1 in the protective effects of

- erythropoietin during renal ischemia/reperfusion injury. *Biochem Pharmacol.* 2010;79(8):1173-81.
3. Ginsberg L. Difficult and recurrent meningitis. *J Neurol Neurosurg Psychiatry* 2004;75(suppl 1):i16-i21.
  4. Puopolo KM. Bacterial and fungal infections. *Manual Neonatal Care.* 2008;6:274-300.
  5. Boyles TH, Bamford C, Bateman K, Blumberg L, Dramowski A, Karstaedt A, et al. Guidelines for the management of acute meningitis in children and adults in South Africa. *South Afr J Epidemiol Infect.* 2013;28(1):5-15.
  6. Griffiths MJ, McGill F, Solomon T. Management of acute meningitis. *J Clin Med.* 2018;18(2):164.
  7. Hoen B, Viel J, Paquot C, Gerard A, Canton P. Multivariate approach to differential diagnosis of acute meningitis. *Eur J Clin Microbiol Infect Dis.* 1995;14(4):267-74.
  8. Koedel U, Klein M, Pfister H-W. Modulation of brain injury as a target of adjunctive therapy in bacterial meningitis. *Curr Infect Dis Rep.* 2010;12(4):266-73.
  9. Parikh S, Koch M, Narayan RK. Traumatic brain injury. *Int Anesthesiol Clin.* 2007;45(3):119-35.
  10. Koedel U, Scheld WM, Pfister H-W. Pathogenesis and pathophysiology of pneumococcal meningitis. *Lancet Infect Dis.* 2002;2(12):721-36.
  11. Østergaard C, Konradsen HB, Samuelsson S. Clinical presentation and prognostic factors of *Streptococcus pneumoniae* meningitis according to the focus of infection. *BMC Infect Dis.* 2005;5(1):1-11.
  12. Agrawal S, Nadel S. Acute bacterial meningitis in infants and children. *Pediatric Drugs.* 2011;13(6):385-400.
  13. Sáez-Llorens X, McCracken Jr GH. Bacterial meningitis in children. *Lancet.* 2003;361(9375):2139-48.
  14. Kastenbauer S, Pfister HW. Pneumococcal meningitis in adults: spectrum of complications and prognostic factors in a series of 87 cases. *Brain.* 2003;126(5):1015-25.
  15. Davison K, Ramsay M. The epidemiology of acute meningitis in children in England and Wales. *Arch Dis Childh.* 2003;88(8):662-4.
  16. Theodoridou MN, Vasilopoulou VA, Atsali EE, Pangalis AM, Mostrou GJ, Syriopoulou VP, et al. Meningitis registry of hospitalized cases in children: epidemiological patterns of acute bacterial meningitis throughout a 32-year period. *BMC Infect Dis.* 2007;7(1):1-12.
  17. Gach O, Lancellotti P, Pierard LA. Acute ST-segment elevation in *Neisseria meningitidis*. *Acta Cardiologica.* 2001;56(5):327-9.
  18. McGill F, Heyderman R, Michael B, Defres S, Beeching N, Borrow R, et al. The UK joint specialist societies guideline on the diagnosis and management of acute meningitis and meningococcal sepsis in immunocompetent adults. *J Infect.* 2016;72(4):405-38.
  19. Schaad UB. Arthritis in disease due to *Neisseria meningitidis*. *Rev Infect Dis.* 1980;2(6):880-8.
  20. Bartt R. Acute bacterial and viral meningitis. *Lifelong Learn Neurol.* 2012;18(6):1255-70.
  21. Chadwick DR. Viral meningitis. *Br Med Bull.* 2005;75(1):1-14.
  22. Ellner JJ, Bennett JE. Chronic meningitis. *Medicine.* 1976;55(5):341-69.
  23. Lan SH, Chang WN, Lu CH, Lui CC, Chang HW. Cerebral infarction in chronic meningitis: a comparison of tuberculous meningitis and cryptococcal meningitis. *Qjm.* 2001;94(5):247-53.
  24. Zunt JR, Baldwin KJ. Chronic and subacute meningitis. *Lifelong Learn Neurol.* 2012;18(6):1290-318.
  25. Charalambous LT, Premji A, Tybout C, Hunt A, Cutshaw D, Elsamadicy AA, et al. Prevalence, healthcare resource utilization and overall burden of fungal meningitis in the United States. *J Med Microbiol.* 2018;67(2):215.
  26. Gottfredsson M, Perfect JR, editors. *Fungal meningitis. Seminars in neurology; 2000: Copyright© 2000 by Thieme Medical Publishers, Inc., 333 Seventh Avenue, New.*
  27. Bicanic T, Harrison TS. Cryptococcal meningitis. *Br Med Bull.* 2004;72(1):99-118.
  28. Dismukes WE. Cryptococcal meningitis in patients with AIDS. *J Infect Dis.* 1988;157(4):624-8.
  29. Powderly WG, Cloud GA, Dismukes WE, Saag MS. Measurement of cryptococcal antigen in serum and cerebrospinal fluid: value in the management of AIDS-associated cryptococcal meningitis. *Clin Infect Dis.* 1994;18(5):789-92.
  30. Lavezzi AM, Corna MF, Maturri L. Neuronal nuclear antigen (NeuN): a useful marker of neuronal immaturity in sudden unexplained perinatal death. *J Neurol Sci.* 2013;329(1-2):45-50.
  31. Gusel'Nikova V, Korzhevskiy D. NeuN as a neuronal nuclear antigen and neuron differentiation marker. *Acta Naturae.* 2015;7(2):42-7.
  32. Korzhevskii DE, Petrova ES, Kirik OV, Beznin GV, EG S. Neural markers in investigation of stem cells differentiation. *Geny Kletki.* 2010;3:57-65.
  33. Zimatkin S, Bon E. Dynamics of Histological Changes in the Frontal Cortex of the Brain in Rats

- Subjected to Antenatal Exposure to Alcohol. *Neurosci Behav Physiol.* 2017;47(3):370-4.
34. Cinzerling AV, VA. C. Modern infections. Pathological anatomy and questions of pathogenesis. . Second edition ed2002.
35. Dolzhikov A, Tverskoi A, Bobyntsev I, Kriukov A, Belykh A. Morphometric study of hippocampal neurons in chronic immobilization stress. *Res Results Biomed.* 2015;1(4):62-5.
36. Maksimova KY, Stefanova N, Logvinov S. Morphological changes in the hippocampus of rats in accelerated aging. *Bull Sibirskoy Meditsiny.* 2014;13(1):56-61.
37. Tverskoi AV, Morozov VN, Petrenko AA, Mukhina TS, Parichuk AS. Morphological characteristics of the rats brain under hypergravity. *Drug Invent Today.* 2017;9:30-2.
38. Zimatkin S, Fedina E. Histaminergic neurons of rat brain after chronic alcohol intoxication. *Novosti Med-Biol Nauk.* 2012(2):137-44.